Combined Endodontic and Surgical Management of a Mandibular Lateral Incisor with a Rare Type of Dens Invaginatus

Antonios M. Chaniotis, DDS, MSc, Giorgos N. Tzanetakis, DDS, MSc,* Evangelos G. Kontakiotis, DDS, PhD,* and Konstantinos I. Tosios, DDS, MSc, PhD†*

Abstract

Dens invaginatus is a developmental malformation of teeth that most commonly affects permanent maxillary lateral incisors. Presence of dens invaginatus in mandibular permanent teeth is relatively rare. The purpose of this report is to describe the combined nonsurgical and surgical management of a mandibular lateral incisor associated with a rare type of dens invaginatus. Pulp involvement of the malformed tooth, periapical abscess, and severe periodontal destruction were observed. The signs (sinus tracts) and symptoms ceased after completion of the treatment. Satisfactory healing of the periradicular lesion was observed at the 6-month and 2-year follow-up examinations. *(J Endod 2008;34:1255–1260)*

Key Words

Dens invaginatus, endodontic surgery, endodontic treatment, tooth malformation

From the *Department of Endodontics and †Department of Oral Pathology, Dental School, University of Athens, Athens, Greece.

Address requests for reprints to Dr E. G. Kontakiotis, Antheon 2, Patisia, 11143 Athens, Greece. E-mail address: ekontak@dent.uoa.gr.

0099-2399/$0 - see front matter

doi:10.1016/j.joen.2008.07.014

Dens invaginatus is a rare developmental malformation of teeth resulting probably from an anomalous infolding of the enamel organ into the dental papilla during tooth development (1). Its prevalence varies significantly and ranges between 0.25%–10% (2–10). However, the issue of the prevalence of dens invaginatus is very complicated as a result of the differences of the relevant conducted studies in terms of their design, the examined sample size, and the diagnostic data used (1, 2).

Oehlers (11) was the first who described 3 different types of dens invaginatus according to the depth of the invagination into the root. However, the more recent classification described by Schulze and Brand (12) is more detailed, illustrating a total of 12 different cases of this anomaly. This classification reports 2 variations (A4, B4) in which the invagination starts laterally and near the incisal edge and continues attached to the external outline of the affected tooth mesially or distally.

Dens invaginatus occurs most commonly in maxillary teeth, lateral incisors, canines, and less frequently in central incisors (13–19). When the malformation occurs in maxillary lateral incisors, bilateral appearance is not uncommon (6). However, dens invaginatus in mandibular teeth (20–23) and specifically in mandibular lateral incisors appears to be a rare condition. Up until now, only 3 clinical cases of this anomaly have been described in the literature (21–23). The first 2 simply reported the cases, and the third described the endodontic treatment of a typical type III dens invaginatus.

The purpose of this report is to describe the combined nonsurgical and surgical management of a mandibular lateral incisor associated with a rare type of dens invaginatus.

Case Report

A 30-year-old male patient with a noncontributory medical history was referred to our private clinic. The clinical and radiologic evaluation concerned the mandibular incisor region where the patient reported he felt repeated pressure. In addition, his sensation on the teeth in the mandibular region was different from other teeth during mastication. The patient reported no history of trauma to the area.

The extraoral examination did not reveal any pathologic signs. During intraoral examination, it was noted that the crown of the right mandibular lateral incisor (tooth #26) was highly asymmetric, especially in the mesiodistal diameter (Fig. 1*A*). No caries was detected on tooth #26 or on the other mandibular incisors. On the lingual surface of tooth #26, a small pit was detected that extended to the mesial surface (Fig. 1*B*). Moderate swelling was noted in the buccal vestibule where the patient was slightly sensitive to palpation. All mandibular incisors were moderately sensitive to percussion, and class 1 mobility was recorded for teeth #26 and 25. No other mobility was detected on the adjacent teeth in the area. Two sinus tracts were detected labially; the first between teeth #26 and 25 and the second between teeth #23 and 22. Periodontal examination revealed deep periodontal pockets at the mesial surface of tooth #26 (11 mm) as well as at the distal surface of tooth #25 (11 mm) and the buccal surfaces of teeth #24 and 25 (10 mm).

Tooth #26 was nonresponsive to both cold and electric pulp testing, indicating a diagnosis of pulp necrosis. Teeth #23, 24, and 25 had no response to cold testing but had delayed responses to electric pulp testing (70–75/80), indicating that irreversible pulpitis in an advanced stage had occurred. Also, electric pulp testing on teeth #22 and

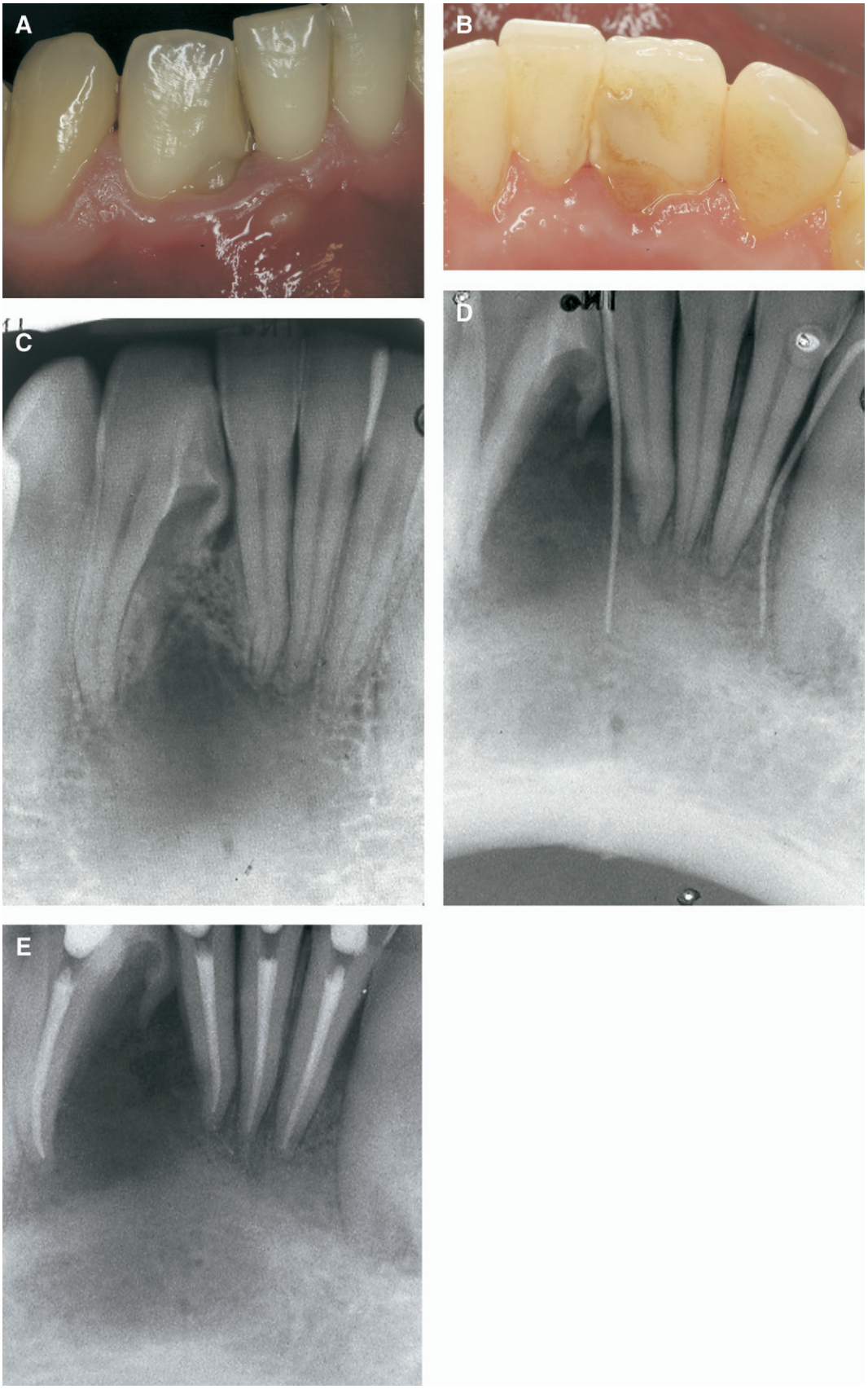

Figure 1. *(A)* Buccal view of right mandibular lateral incisor. Note the fistula and the asymmetry of the crown. *(B)* Lingual view of right mandibular lateral incisor. A small pit is detected under magnification 8×. *(C)* Preoperative periapical radiograph. *(D)* A second periapical radiograph with 2 gutta-percha cones in place showing the sinus tracts. *(E)* Postoperative radiograph.

27 showed normal responses of the pulp. Clinical examination of the surrounding teeth did not reveal any other clinical signs or symptoms.

The panoramic and periapical radiographs (Fig. 1*C*) revealed a large periapical radiolucency associated mainly with tooth #26 but also with the adjacent teeth #24 and 25. Regarding tooth #26, an unusual morphology of the crown and the root was observed at the mesial surface. An extensive radiopaque projection was observed attached to the crown of the tooth and was probably lined by enamel, as could be presumed by the radiopacity of its surface outline. This projection has the appearance of an invagination attached to the outline surface of the root under the cementoenamel junction.

Additional periapical radiographs were exposed with 2 gutta-percha cones in place to reveal the pathways of the 2 sinus tracts (Fig. 1*D*). The first sinus tract was associated with the large periradicular lesion between teeth #26 and 25, whereas the second ended in the area between teeth #23 and 22. This radiograph made us suspect that the periradicular lesion was not limited to the area between teeth #26 and 25 but possibly extended to the radicular region of the left mandibular canine (#22). Because of these clinical and radiographic findings, it was decided to endodontically treat the 4 mandibular incisors in 1 visit and to schedule the surgical treatment at a subsequent appointment.

Endodontic Treatment

After administrating local anesthesia (1.7 mL Ubistesin forte, articaine, 1:100,000 epinephrine) the 4 mandibular incisors were simultaneously isolated with a rubber dam. Access cavity preparations were performed by using Endo-Access diamond bur (Dentsply, Maillefer, Baillaigues, Switzerland). Access opening of tooth #26 was modified according to the external morphology of the crown. Despite this, an interconnection between the main canal and the malformation or a second independent canal could not be detected under high magnification of 19.2×. Initial investigation of the root canal system in all incisors was performed with a size 10 K-file (Dentsply, Maillefer). An apex locator (Bingo 1020; Forum Technologies, Rishon Lezion, Israel) was used to verify working lengths. All 4 canals were instrumented to a master apical size 35 by hand. Individual canal flaring was performed with HERO 642 (Micro-Mega, Rue du Tunnel, France) rotary nickel-titanium no. size 30 0.06 taper files. During instrumentation, a total of 100 mL of 2.5% sodium hypochlorite was used for the irrigation of the canals of the 4 mandibular incisors. After completion of the chemomechanical preparation, root canals were dried with sterile paper points. All the above procedures were performed under a dental operating microscope (Global, Protégé plus; Global Surgical Corporation, St Louis, MO).

Obturation was performed with a System B heat source (SybronEndo Corporation, Orange, CA) by using fine-medium nonstandardized gutta-percha cones and AH-26 sealer (Dentsply, De Trey, GmbH, Konstanz, Germany). Additional vertical condensation was performed by using finger pluggers of ISO size #40. The backfilling was performed with thermoplasticized gutta-percha from an Obtura II (Obtura Spartan, Fenton, MO). A temporary filling (Cavit G; 3M ESPE, Seefeld, Germany) was placed, and a postoperative radiograph was exposed to assess the quality of obturation in all 4 canals (Fig. 1*E*).

Surgical Management

Two days after the completion of the treatment, the patient presented in our office without any clinical symptoms. A full-thickness mucoperiosteal flap was raised under inferior alveolar block anesthesia in the right mandibular region and local infiltration in the left anterior mandibular region (buccal and lingual). A large soft lesion was revealed involving the roots and the apices of all mandibular incisors (Fig. 2*A*). The lesion was then circumferentially separated from the bony crypt and teeth. The lesion was then removed, clearly revealing the malformation and its limits (Fig. 2*B, C*). A thin conical diamond bur was used to circumferentially remove the malformation as atraumatically as possible. Both the periradicular lesion and the tooth fragment were fixed in 10% buffered formalin solution for histologic evaluation. The remaining root was then smoothed with diamond burs.

Two collagen membranes were placed around the bony defect and stabilized by using titanium pins on the surrounding healthy bone. After the placement of the membranes, the mucoperiosteal flap was sutured in place, and a periapical radiograph was taken to confirm the accuracy of the surgical manipulations (Fig. 2*D*). Healing was uneventful, and 6 months postoperatively the patient was free of any signs and symptoms, and the teeth had been permanently restored. The clinical appearance of the anterior mandibular area was acceptable (Fig. 3*A*). The radiographic examination revealed that partial healing of the lesion had occurred (Fig. 3*B*). The patient was recalled 2 years postoperatively for clinical and radiographic examination. At that time, the patient was symptom-free. The clinical appearance of the area was satisfactory (Fig. 3*C*). The radiographic examination revealed that a great part of the lesion had been covered with healthy bone (Fig. 3*D*). No periodontal pockets were detected in the area during the periodontal examination at that time.

Histologic Evaluation

Both the lesion and the invagination process were paraffin-embedded and processed for microscopic examination. Hematoxylin-eosin–stained sections of the lesion showed fragments of inflammatory connective tissue lined by nonkeratinized stratified squamous epithelium containing many hyaline rings. The diagnosis was consistent with a periradicular cyst. Examination of the invagination revealed initially enamel as well as dentin covered by cementum with an unusual "global" morphology and periodontal connective tissue. The presence of a lumen in the center of dentin was suggestive of the presence of a rudimentary pulp canal space that was not evident clinically or radiographically (Fig. 3*E*).

Discussion

The etiology of dens invaginatus malformation is still controversial and remains unclear. Numerous theories have been suggested, including altered tissue pressures, trauma, infection, or localized discrepancies in cellular hyperplasia (1). However, the more significant issue remains the correct diagnosis and subsequent proper management on the basis of sound biologic and clinical principles (24).

The present clinical article describes the combined endodontic and surgical management of a mandibular lateral incisor associated with a rare type of dens invaginatus and a large periradicular lesion. This type of management has been proposed in the literature in cases in which the chemomechanical preparation of conventional endodontic therapy appears unable to remove all the irritants located inside the root canal system with this aberrant morphology (25, 26). According to the classification made by Schulze and Brand (12), it seems that this malformation shows a broad spectrum of morphologic variations. This view is confirmed by the presence of such anomalies as the present case in which the diagnosis is extremely difficult.

In such cases, an intercanal connection might exist between the main root canal and the invagination process (9). In the present case, no communication was detected between the main canal and the malformation radiographically or clinically, even under high magnification. This does not mean that there was not any connection between the pulp canal cavity and the internal space of the malformation, even through the dentinal tubules of the underlined dentin. The first possible strong evidence of this was the presence of the lumen detected histologically

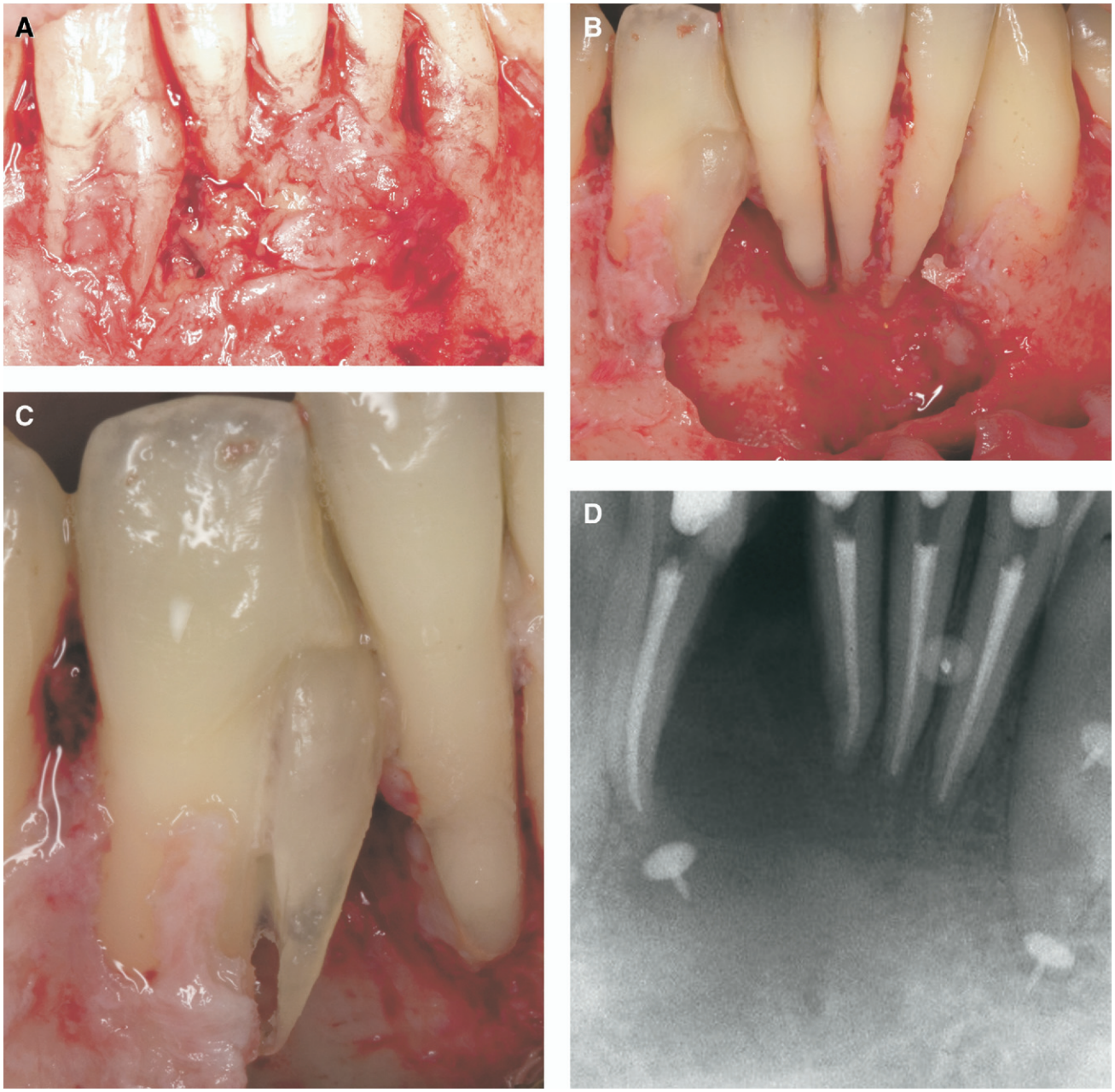

Figure 2. *(A)* Clinical view of the lesion after the flap design has been reflected. *(B)* The malformed structure attached to the mesial surface of the mandibular incisor under magnification 3.2×. *(C)* The malformed structure under magnification 5.1×. *(D)* Periapical radiograph after completion of surgery.

into the dentin part center of the malformed structure. The second concerns the pulp necrosis that occurred in a tooth with intact crown and without any caries detection.

During the surgical management of the present case, a barrier membrane technique was used to obtain the best healing result. This was done for 3 reasons. The first concerned the size of the lesion and the lack of the buccal cortical plate in the area. The second was the prevention of the invasion of competing nonosteogenic cells into the bony defect from the overlying soft tissues. The third was correlated with the nature of the lesion (endo-perio). Pulp necrosis of the involved tooth (#26) in combination with the location of the malformed structure had provoked a severe periodontal destruction in the area involving the other 3 mandibular incisors.

The removal of the malformation exposed a small area of dentin to the oral environment. This matter is of foremost clinical significance. Flowable composite resin was applied to cover the exposed dentin. Periodic examination and protection of the area are necessary in the future to prevent the contamination of the dentinal tubules.

The majority of the described procedures were performed under the operating microscope with a range of magnifications between 5.1–12.8×. On the basis of the literature, the dental operating microscope is considered to be a very useful device during the management of endodontic cases with aberrant anatomy (27). In this case, the microscope helped primarily during the surgical removal of the malformed structure. Inspection of the entire root surface was also performed

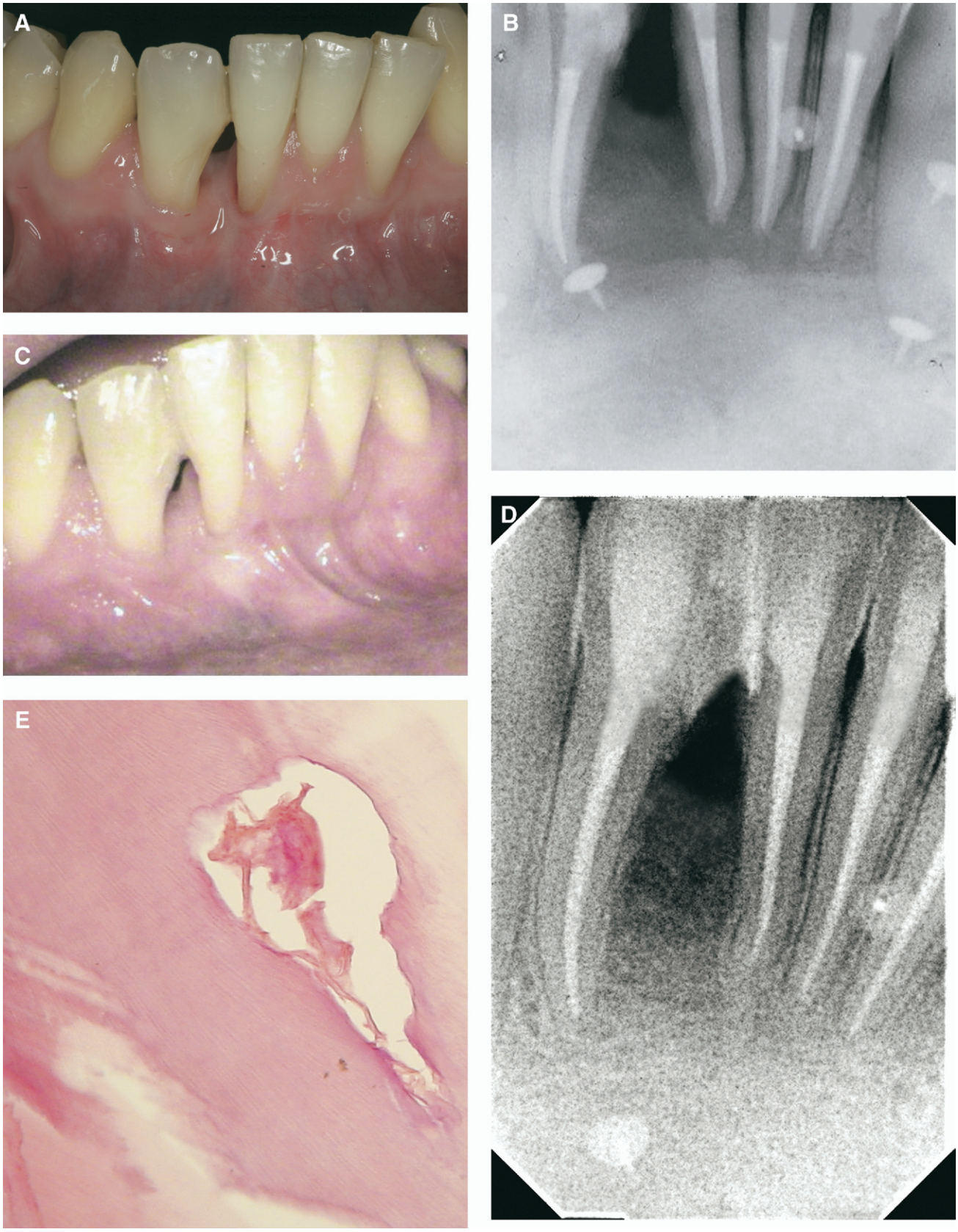

Figure 3. *(A)* Clinical appearance of mandibular region 6 months after surgery. *(B)* Periapical radiograph 6 months after surgery. *(C)* Clinical appearance of the area 2 years after surgery. *(D)* Periapical recall radiograph 2 years after surgery. *(E)* Dentin-lined lumen suggesting the existence of rudimentary pulp canal space (hematoxylin-eosin stain; original magnification, ×400).

under high magnification. Under these circumstances, the treatment outcome can be predictable and successful.

References

1. Hulsmann M. Dens invaginatus: aetiology, classification, prevalence, diagnosis, and treatment considerations. Int Endod J 1997;30:79–90.
2. Hovland E, Block R. Non-recognition and subsequent endodontic treatment of dens invaginatus. J Endod 1977;3:360–2.
3. Poyton GH, Morgan GA. Dens in dente. Dent Radiogr Photogr 1966;39:27–33.
4. Ruprecht A, Batniji S, Sastry K, El-Neweihi E. The incidence of dental invagination. J Pedod 1986;10:265–72.
5. Ulmansky M, Hermel J. Double dens in dente in a single tooth. Oral Surg Oral Med Oral Pathol 1964;17:92–7.
6. Grahnen H, Lindahl B, Omnell K. Dens invaginatus: I—a clinical, roentgenological and genetical study of permanent upper lateral incisors. Odontologisk Revy 1959;10:115–37.
7. Fujiki Y, Tamaki N, Kawahara K, Nabae M. Clinical and radiographic observations of dens invaginatus. J Dentomaxillofac Radiol 1974;3:343–8.
8. Thomas JG. A study of dens in dente. Oral Surg Oral Med Oral Pathol 1974;38:653–5.
9. Gotoh T, Kawahara K, Imai K, Kishi K, Fujiki Y. Clinical and radiographic study of dens invaginatus. Oral Surg Oral Med Oral Pathol 1979;48:88–91.
10. Ruprecht A, Sastry K, Batniji S, Lambourne A. The clinical significance of dental invagination. J Pedod 1987;11:176–81.
11. Oehlers FA. Dens invaginatus: I—variations of the invagination process and associated anterior crown forms. Oral Surg Oral Med Oral Pathol 1957;10:1204–18.
12. Schulze C, Brand E. Über den dens invaginatus (dens in dente). Zahnärztliche Welt/Reform 1972;81:569–73, 613–20, 653–60, 699–703.
13. Benenati WF. Complex treatment of a maxillary lateral incisor with dens invaginatus and associated aberrant morphology J Endod 1994;20:180–2.
14. Gound GT, Maixner D. Nonsurgical management of a dilacerated maxillary lateral incisor with type III dens invaginatus: a case report. J Endod 2004;30:448–51.
15. Nallapati S. Clinical management of a maxillary lateral incisor with vital pulp and type 3 dens invaginatus: a case report. J Endod 2004;30:726–31.
16. Steffen H, Splieth C. Conventional treatment of dens invaginatus in maxillary lateral incisor with sinus tract: one year follow-up. J Endod 2005;31:130–3.
17. Stamfelj I, Kansky AA, Gaspersic D. Unusual variant of type 3 dens invaginatus in a maxillary canine: a rare case report. J Endod 2007;33:64–8.
18. Lichota D, Lipski M, Wozniak K, Buczkowska-Radlinska J. Endodontic treatment of a maxillary canine with type 3 dens invaginatus and large periradicular lesion: a case report. J Endod 2008;34:756–8.
19. Duckmanton PM. Maxillary permanent central incisor with abnormal crown size and dens invaginatus: case report. Endod Dent Traumatol 1995;11:150–2.
20. Er K, Kustarci A, Ozan U, Tasdemir T. Nonsurgical endodontic treatment of dens invaginatus in a mandibular premolar with large periradicular lesion: a case report. J Endod 2007;33:322–4.
21. Conklin WW. Bilateral dens invaginatus in the mandibular incisor region. Oral Surg Oral Med Oral Pathol 1978;45:905–8.
22. Khabbaz MG, Konstantaki MN, Sykaras SN. Dens invaginatus in a mandibular lateral incisor. Int Endod J 1995;28:303–5.
23. Muppararu M, Singer SR. A rare presentation of dens invaginatus in a mandibular lateral incisor occurring concurrently with bilateral maxillary dens invaginatus: case report and review of literature. Aust Dent J 2004;49:90–3.
24. Ikeda H, Yoshioka T, Suda H. Importance of clinical examination and diagnosis: a case of dens invaginatus. Oral Surg Oral Med Oral Pathol Oral Radiol Endod 1995;79:88–91.
25. Ortiz P, Weisleder R, Villareal de Justus Y. Combined therapy in the treatment of dens invaginatus: case report. J Endod 2004;30:672–4.
26. Kulild JC, Weller N. Treatment considerations in dens invaginatus. J Endod 1989;15:381–4.
27. Girsch WJ, McClammy TV. Microscopic removal of dens invaginatus. J Endod 2002;28:336–9.