J Oral Maxillofac Surg
50:304-306, 1992

Metastatic Breast Carcinoma of the Masseter:

Case Report

KONSTANTINOS TOSIOS, DDS,* ANTONIOS VASILAS, DDS,† AND ADAMANDIOS ARSENOPOULOS, DDS‡

Skeletal muscle metastases are considered quite unusual.[1-3] Autopsy series have reported incidences of 0.8%[4] to 52.4%,[5] depending on the number of muscles and type of malignant neoplasms studied, but clinically apparent involvement is very rare.[1,6,7] The literature consists mainly of isolated case reports.[1-3,6-13]

Clinical presentation of intramuscular metastases is nonspecific. Diagnosis is established by microscopic examination, which reveals nodular[1,14] or diffuse[3,5-8,10,15] infiltration of the connective tissue between muscle bundles by neoplastic cells.

A case of metastatic breast carcinoma presenting as a firm enlargement of the masseter is reported. The histology of the lesion was unusual, as neoplastic cells were seen infiltrating individual myofibers.

Report of Case

A 57-year-old woman was seen in February 1988 with an 8-month history of gradual swelling of the right side of her face and difficulty with mouth opening. She related these symptoms to the extraction of her lower right third molar. Antibiotics and vitamins were unsuccessful in resolving the swelling. Her past medical history disclosed that in May 1986 she had a left radical mastectomy for a moderately differentiated, infiltrative ductal carcinoma. The axillary lymph nodes were uninvolved. Local recurrence or metastatic spread had not been recorded since the operation.

Physical examination showed a diffuse, edematous swelling of the right side of the face (Fig 1). A slightly painful, indurated enlargement of the masseter, which was not fixed to the overlying skin, could be palpated. Intense trismus and deviation of the mandible to the left was noted on attempted mouth opening. The oral mucosa was normal and the extraction site had healed. No palpable lymph nodes were evident. A panoramic radiograph of the jaws did not reveal any bone involvement (Fig 2). Submasseteric abscess and metastatic carcinoma were considered in the differential diagnosis. Conservative treatment was decided on, and the patient was asked to perform hot irrigations for several days. Progress was unsatisfactory and, as a metastatic lesion was also suspected, an exploration of the submasseteric space was performed. After a wide intraoral incision was made at the anterior aspect of the ascending ramus, a mass was seen protruding from the masseter muscle. The adjacent mandibular bone was examined for signs of infiltration, but none was evident. Portions of the mass were removed for histologic examination.

Grossly, the excised tissue specimens, measuring 2 × 1.5 × 0.5 cm, were gray-white and of elastic consistency. Histologic sections showed areas of fibrous connective tissue, striated muscle, and peripheral nerves diffusely infiltrated by neoplastic cells (Fig 3). The cells were mainly arranged in compact groups, lobules, and threadlike strands, and contained dark-staining or vesicular nuclei, with eosinophilic cytoplasm. Some cells with clear cytoplasm were also seen. There were few mitotic figures. An unusual feature was the presence of groups of neoplastic cells inside the sarcoplasm of individual myofibers, surrounded by a rim of residual sarcoplasm (Figs 3, 4). A diagnosis of carcinoma of unknown origin, possibly metastatic, was made. Comparative study with sections from the primary breast tumor confirmed the origin of the lesion.

The patient was referred to a specialized cancer treatment center. Contrast-enhanced computed tomography (CT) of the head and neck showed marked enlargement of the right masseter, without bony abnormality. In April 1988, a radionuclide bone scan with technetium Tc 99m methylene diphosphonate (MDP) revealed increased uptake in the area of the right mandible, which was attributed to isotope localization in the masseteric lesion. Fine-needle aspiration biopsy was positive for metastatic breast carcinoma. Metastases in the liver, sacrum, and pelvis were also detected. Combination chemotherapy with adriamycin, 5-fluorouracil, and endoxan was started, and on completion of one course, palliative irradiation of the masseter with cobalt 60 was delivered. Four weeks later, the swelling and pain had nearly resolved, but jaw movement was still restricted. Repeated radiographic examination of the jaws was normal, but a CT scan of the head and neck showed slight enlargement of the right masseter

Received from the Dental School, University of Athens, Athens, Greece.
* Postgraduate Student, Department of Oral Pathology.
† Postgraduate Student, Department of Oral and Maxillofacial Surgery.
‡ Staff, Department of Oral and Maxillofacial Surgery.
Address correspondence and reprint requests to Dr Tosios: 105 Lykourgou, 17676 Athens, Greece.

0278-2391/92/5003-0020$3.00/0

FIGURE 1. Clinical photograph showing diffuse swelling of the right side of the face.

and lateral pterygoid muscle. Five more courses of chemotherapy were given. In November 1988, surgical excision of the masseteric metastasis was performed in an attempt to improve the mobility of the mandible, but the results were unsatisfactory. Repeated radiographic examination was negative for mandibular metastases, but a ^{99m}Tc MDP bone scan showed increased uptake in T-8 and the 7th, 8th and 9th ribs, but no mandibular "hot spots." Eleven months after initial presentation, the patient was lost to follow-up.

Discussion

Skeletal muscle involvement by a metastatic neoplasm is considered quite uncommon.[1-3] An autopsy survey of 500 consecutive cases[4] revealed only four cases (0.8%) of intramuscular metastases. Pearson,[15] in a similar study in which nine different muscles were sampled, found six cases in 38 cancer patients (16%). The author attributed the higher incidence to the number of muscles sampled and postulated that the possibility of detecting metastases "increases almost in proportion to the number of muscles examined." Buerger and Monteleone,[5] examining 12 muscles per case in 82 leukemia and lymphoma patients, confirmed 43 cases of muscle involvement (52.4%). It should be emphasized that these metastases were not grossly recognized[15] and were revealed only microscopically.[7] An autopsy study of 12 patients with metastasis in various parts of the tongue[14] reported four cases of muscle involvement, including one located in the musculature of the tongue.

In contrast to these high incidences, the presence of a clinically apparent intramuscular metastasis is very rare,[1,6,7] with few cases reported. Of those muscles involved, the extraocular muscles are commonly affected,

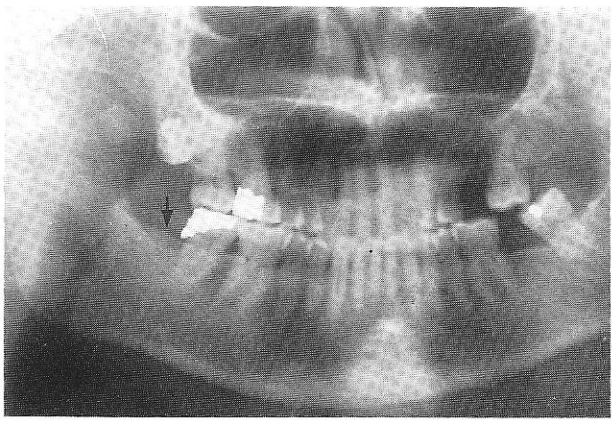

FIGURE 2. Panoramic radiograph showing normal healing of the extraction site of the lower third molar (arrow).

with 31 cases reported as of 1990.[13] Carcinoma of the breast and malignant melanoma, with incidences of 55% and 21%, respectively, made up the majority of metastatic tumors.[13] Metastases in the limb muscles from carcinoma of the lung,[3,9,11] colon,[2,12] breast[3] and from lymphoma[6,10] have also been reported. Muslow[1] described a case of pancreatic carcinoma presenting with multiple metastases in many muscles of the limb and trunk. A single case of metastasis in a paraspinal muscle from a breast carcinoma was recorded by Yoshi and Montana.[7] A gastric adenocarcinoma metastatic to the tongue muscles was reported by Weitzner and Hentel.[8] The greater survival of cancer patients resulting from modern therapeutic methods is expected to increase the number of muscle metastases discovered clinically.

Skeletal muscle metastases present as focal or diffuse hard enlargements of the affected muscle[1,2,6-12] associated with pain[1,2,6-8,10-13] and impaired function.[1,7,8,11,13] Altered sensation,[2,3,6] proximal weak-

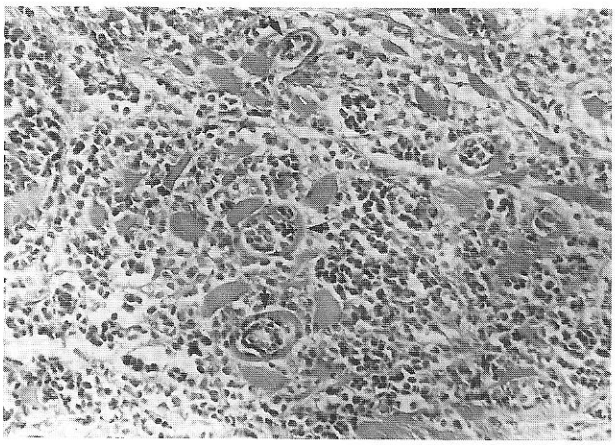

FIGURE 3. Area of muscle tissue diffusely infiltrated by neoplastic cells. Note groups of neoplastic cells inside the sarcoplasm of individual myofibers (arrows) (hematoxylin-eosin, original magnification ×25).

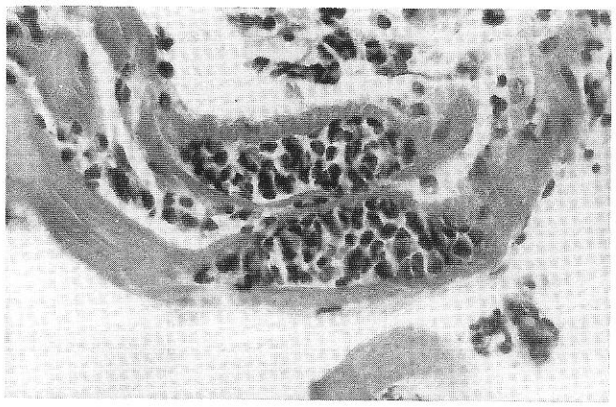

FIGURE 4. Groups of neoplastic cells inside the sarcoplasm of longitudinally cut myofibers. Note intact rim of residual sarcoplasm (hematoxylin-eosin, original magnification ×40).

ness,[3,10,11] wasting,[3] and electromyographic findings of a myopathic process[3,7] have also been reported. In some cases there is a similarity to inflammatory disease in clinical presentation.[2,10,13]

Computed tomography shows focal[13] or diffuse[7,10,13] enlargement, with feathering of the muscle's edge and loss of normal fascial planes between muscle groups.[7,10] These findings are nonspecific,[7,10,13] but the presence of a primary neoplasm in the body should arouse suspicion of metastasis. Magnetic resonance imaging does not add specificity to the information acquired by CT.[13] Soft-tissue localization of ^{99m}Tc polyphosphate has been reported for several malignant neoplasms, including breast adenocarcinoma.[16]

The reason for the rarity of striated muscle metastases is not known. It has been proposed that the continuous contraction and variable vascular flow in muscle tissue might prevent the mechanical arrest of metastatic emboli,[1,11] whereas the unsuitable environment caused by pH alterations and accumulation of lactic acid,[1,11] high oxygen tension, and immunoreactivity of muscle tissue[11] could inhibit tumor growth. The presence of site-specific growth modulators and the properties of malignant cells have also been considered.[11]

Histologically, metastatic involvement of skeletal muscle manifests in the form of nodular[14,15] or diffuse[3,5-8,10,15] neoplastic infiltration of the connective tissue of the perimysium or endomysium. The latter mode of involvement is mainly seen in highly malignant and anaplastic neoplasms and has been described for breast carcinomas.[7] Compression and atrophy of muscle fibers due to neoplastic infiltration is a common finding.[7] Differential diagnosis of such lesions from other small-cell malignancies may be difficult.[6,10] Infiltration of individual myofibers by neoplastic cells, without obvious destruction of the sarcolemma sheath as was seen in the present case, is extremely rare[3,5,17] and has been reviewed in detail by Sarma et al.[17]

The presence of intramuscular metastases are considered a sign of generalized spread and poor prognosis.[11] Therapeutic intervention is mainly palliative, and no curative treatment is known.[11] Surgical excision of the involved muscle[2,12] and combination chemotherapy[3,6,10] have been used successfully in a few cases of metastatic carcinoma and lymphoma. In the present case, an attempt to improve the jaw mobility with surgical excision of the metastasis was not successful. Various schemes of radiotherapy have also been recommended for the palliation of pain.[11] Radiotherapy succeeded in checking the muscle enlargement and pain in the case reported.

References

1. Muslow FW: Metastatic carcinoma of skeletal muscles. Arch Pathol 35:112, 1943
2. Laurence AE, Murray AJ: Metastasis in skeletal muscle secondary to carcinoma of the colon. Presentation of two cases. Br J Surg 57:529, 1970
3. Doshi R, Fowler T: Proximal myopathy due to discrete carcinomatous metastases in muscle. J Neurol Neurosurg Psych 46:358, 1983
4. Willis RA: The Spread of Tumors in the Human Body. London, UK, Butterworth, 1973, p 282
5. Buerger LF, Monteleone PN: Leukemic-lymphomatous infiltration of skeletal muscle. Systematic study of 82 autopsy cases. Cancer 19:1416, 1966
6. Kandel RA, Bedard YC, Pritzker KPH, et al: Lymphoma presenting as an intramuscular small cell malignancy. Cancer 53: 1586, 1984
7. Yoshi C, Montana M: CT findings of metastatic breast carcinoma involving muscle. J Comput Assist Tomogr 95:967, 1985
8. Weitzner S, Hentel W: Metastatic carcinoma in tongue. Report of a case. Oral Surg 25:278, 1968
9. Pellegrini AE: Carcinoma of the lung occurring as a skeletal muscle mass. Arch Surg 114:550, 1979
10. Grem JL, Neville AJ, Smith SC, et al: Massive skeletal muscle invasion by lymphoma. Arch Intern Med 145:1818, 1985
11. Sridhar KS, Rao RK, Kunhardt B: Skeletal muscle metastases from lung cancer. Cancer 59:1530, 1987
12. Torosian MH, Botet JF, Paglia M: Colon carcinoma metastatic to the thigh—An unusual site of metastasis. Report of a case. Dis Colon Rectum 30:805, 1987
13. Capone A, Slamovits TL: Discrete metastasis of solid tumors to extraocular muscles. Arch Ophthalmol 108:237, 1990
14. Zegarelli DJ, Tsukada Y, Pickren JW, et al: Metastatic tumor to the tongue. Report of twelve cases. Oral Surg 35:202, 1973
15. Pearson CM: Incidence and type of pathologic alterations observed in muscle in a routine autopsy survey. Neurology 9: 757, 1959
16. Thrall JH, Ghaed N, Geslien GE, et al: Pitfalls in Tc^{99m} polyphosphate skeletal imaging. AJR 121:739, 1974
17. Sarma DP, Weilbaecher TG, Love GL: Intramyofiber metastasis in skeletal muscle. J Surg Oncol 30:103, 1985